

# Schwannoma of the Spinal Accessory Nerve: A Case Report

RITESH KOHLI<sup>1</sup>, SURINDER SINGH<sup>2</sup>, ASHWANI K. GUPTA<sup>3</sup>, PRITHPAL S. MATREJA<sup>4</sup>

## ABSTRACT

We are reporting a rare case of a schwannoma which originated from the cervical portion of the spinal accessory nerve, which was located in the left posterior triangle of the neck and did not have any neurological deficit, which was diagnosed by the Magnetic Resonance Imaging (MRI) scan and confirmed histopathologically after surgery.

## INTRODUCTION

The schwannomas have been referred to as neurilemmomas, neuromas, or neurinomas with an unknown originating cause [1,2]. Schwannomas are uncommon benign nerve sheath tumours that originate from any cranial, peripheral or autonomic nerve of the body, with the exception of the olfactory and the optic nerves [1-3]. Some 25-50% cases of the reported schwannomas have a predilection for the head and neck [1,2,4], which pose a diagnostic and a management challenge [2]. The schwannomas which occur in the head and neck region mostly originate from the vagus nerve or from the sympathetic nervous system [4]. They are usually solitary asymptomatic nodule masses which are slow growing in the soft tissue and are painless unless they cause pressure on the adjacent nerves [1]. Various preoperative image studies have been used to distinguish their locations and origins [4]. The accepted treatment of Schwannomas is surgical excision and surgical modalities, which preserve the neurological function [1,4].

A total of 28 cases of spinal accessory nerve schwannomas have been reported, among which four were reported in the craniocervical region, which extended from C1 or C2 to the vermis, with only two being located in the cervical region [5,6]. We are reporting here, a rare case of an accessory nerve schwannoma in the cervical region.

## CASE REPORT

A 17 year old girl presented to the Department of Surgery with the complaint of a painless, slow growing lump on the left side of neck, over a period of 1 year. There was no remarkable personal or family history. The swelling was an oval mass of size, 6 cm by 5 cm, which was located in the posterior triangle of the neck. The swelling was soft, cystic and mobile, with well defined margins and no pressure symptoms. There was no tenderness [Table/Fig-1]. The neurological examinations showed that the neck muscles on both the sides were symmetric. The trapezius and the sternocleidomastoid were similar in power, tone and trophism on both the sides.

The patient underwent complete blood count and urine culture examinations, which were found to be within normal limits. Ultrasonography was advised to know whether the tumour was located between the jugular vein and the carotid artery. Magnetic Resonance Imaging (MRI) was done with the use of Gadolinium based contrast media, for determining the exact nerve of origin [Table/Fig-2].

A surgical resection of the tumour was planned under general anaesthesia. The tumour was resected by doing a lateral cervical approach incision. A well circumscribed, encapsulated, yellowish

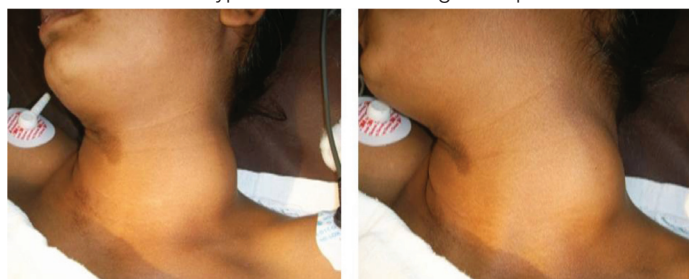
**Key words:** Schwannoma, Accessory nerve, Tumour, Nerve sheath

white, shiny mass was found to grow within the substance of the spinal accessory nerve.

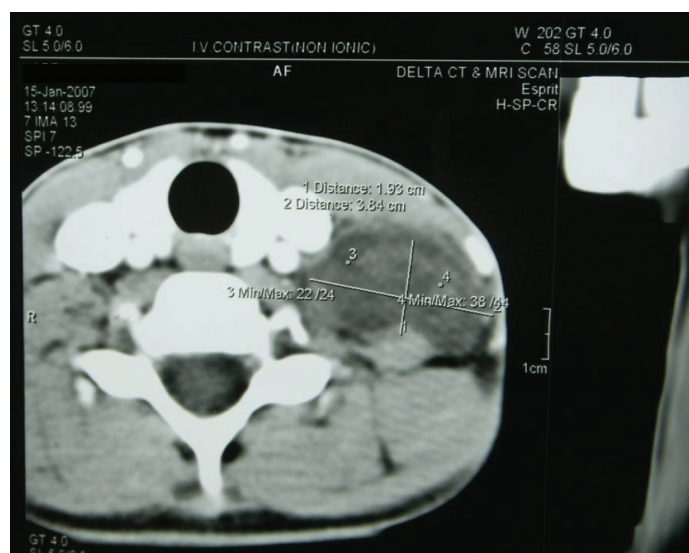
The tumour was resected by displacing the uninvolved fascicles which were running between the leaves of the capsule, and not entering the tumour itself. The tumour was extending into the neural canal but it was easily separated by doing a blunt dissection and by applying a mild traction to the tumour. Total excision of the tumour and the entire capsule was done [Table/Fig-3].

The cut section of the tumour demonstrated that it was well encapsulated and gray white on the cut section [Table/Fig-4]. The specimen was sent for a histopathological examination.

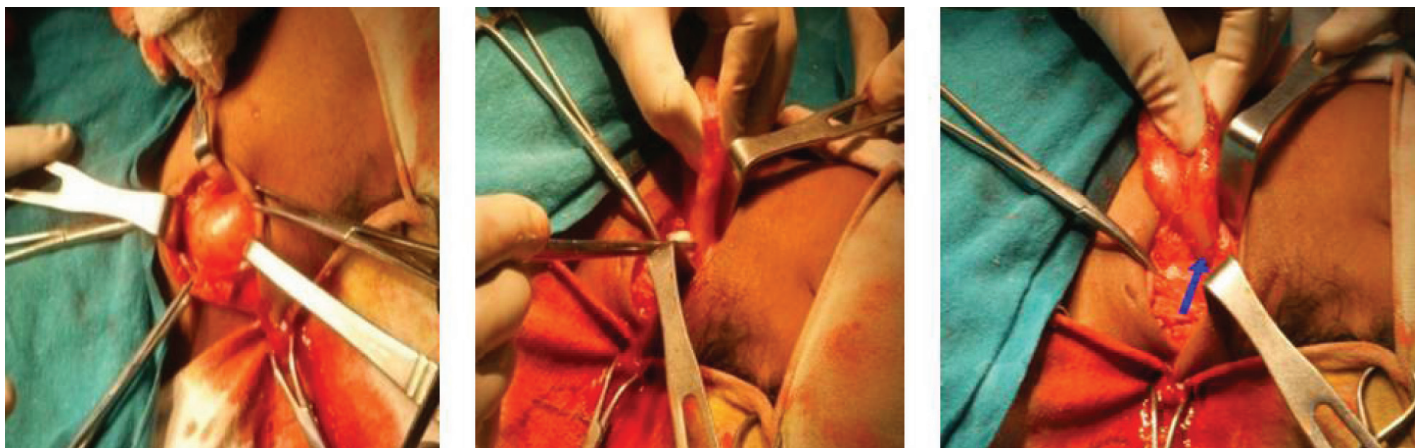
The histopathology demonstrated schwann cells in a collagenous matrix. The Antoni Type A tissue had elongated spindle cells which



**[Table/Fig-1]:** Clinical Presentation of patient with Schwannoma



**[Table/Fig-2]:** MRI scan showing the location and dimension of Schwannoma



[Table/Fig-3]: Surgical approach to the patient with Schwannoma (Arrow)

were arranged in irregular streams and was compact in nature, whereas, the Antoni type B tissue had a looser organization, often with cystic spaces being intermixed within the tissue [Table/Fig-5].

During the postoperative period, the patient developed weakness of the trapezius muscle and was unable to abduct the left arm. The patient was advised physiotherapy and after one month of discharge, the patient was able to abduct her left arm and there was no other neurological deficit .

## DISCUSSION

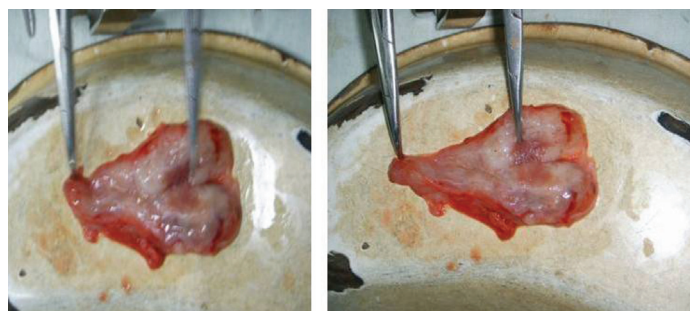
A schwannoma is a relatively slow growing tumour of the nerve sheath, which is composed of the schwann cells, which normally produce the insulating myelin sheath which covers the peripheral nerves. They are homogenous tumours and they always stay on the outside of the nerve and may push the nerve aside or against the bony structure [7].

The schwannomas which occur in the head and neck region mostly originate from the vagus nerve or from the sympathetic nervous system [4]. Most of the cases present with an asymptomatic stable neck mass that causes little concern, other than the possibility of a malignancy and cosmesis [2]. The intracranial accessory nerve schwannomas could be either of the jugular foramen type, the intracisternal type, or of the cervical type. The lower cranial nerves which include the glossopharyngeal nerve, the vagus and the accessory nerve, form a complex at the jugular foramen, which is defined as a jugular foramen schwannoma without the identification of the individual cranial nerve [8].

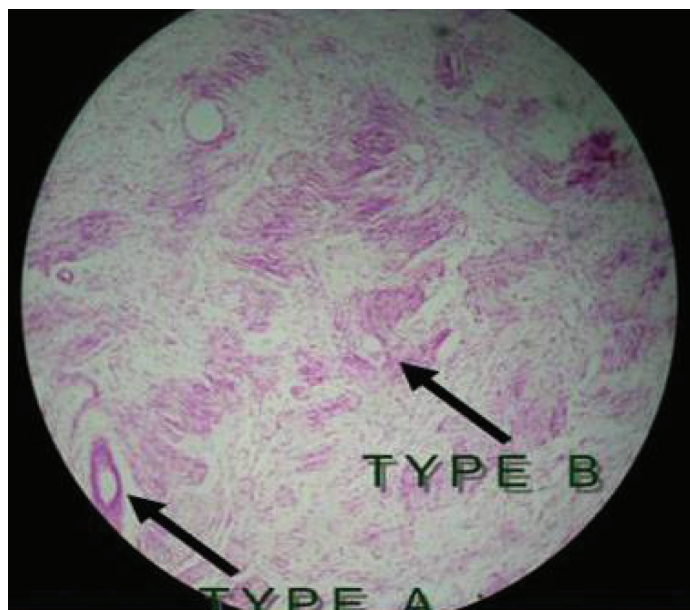
Imaging studies help in the accurate diagnosis of schwannomas, with a reasonably good accuracy. The modalities like MRI scans are very helpful in identifying the tumours and their correlations with the surrounding vascular structures, muscles, and nerves [4]. In addition, preoperative imaging provides information on the tumour size, location, extent and the surrounding anatomy, and it enables the surgical planning [2].

A gross total resection remains the treatment of choice for these tumours, because they are radio resistant. This tumour is confirmed on the histopathological section, which shows the presence of the Antoni type A and type B cells. The tumours which originate in the Schwann cells can be detected during immune-histochemical examinations, by virtue of their positive results for the S-100 antigen test [1,5].

The other treatment option is stereotactic radiosurgery (SRS). SRS is gaining popularity, but it depends on many factors, which include the size and the location of the Schwannoma and the age of the patient. Whenever it is possible, SRS should be avoided in young patients [9].



[Table/Fig-4]: Cut section of Schwannoma



[Table/Fig-5]: Histopathological section of Schwannoma demonstrating Antoni Type A tissue with elongated spindle cells arranged in irregular streams and compact in nature; and Antoni type B tissue with looser organization, often with a cystic spaces intermixed within tissue

## CONCLUSION

The initial evaluation of the patients with suspected cervical nerve tumours should include the history, clinical assessment, focusing on the stigmata on a family history of neurocutaneous disease and a complete examination of the head and neck, to rule out other neck masses. The primary treatment of the Schwannomas which originate from the cervical portion of the spinal accessory nerve is resection of the total tumour, with sacrifice of the involved nerve. Usually, no postoperative dysfunction of the nerve occurs.

## REFERENCES

- [1] Chen TW, Chen CJ, Leung KW. Recurrent schwannoma of upper neck: A case report. *Taiwan J Oral Maxillofac Surg.* 2009; 20: 60-7.
- [2] Kang GCW, Soo KC, Lim DTH. Extracranial non-vestibular head and neck schwannoma: A ten year experience. *Ann Acad Med Singapore.* 2007; 36: 233-40.
- [3] Tay HL, Swanston AR, Lumley JSP. Glossopharyngeal schwannoma presenting as gagging dysphagia. *Postgrad Med J.* 1994; 70: 207-9.
- [4] Kim SH, Kim NH, Kim KR, Lee JH, Choi HS. Schwannoma in head and neck: Preoperative imaging study and intracapsular enucleation for functional nerve preservation. *Yonsei Med J.* 2010; 51: 938-42.
- [5] Tatebayashi K, Tanaka Y, Numata H, Kawakami S, Kamitani H, Watanabe T. Schwannoma of the spinal accessory nerve in the cistern magna. *Surgical Neurology.* 2003; 59: 217-22.
- [6] Kaynar MY, Hanci M, Sarioglu AC. Intraspinal schwannoma of the accessory nerve. *British Journal of Neurosurgery.* 1999; 13: 429-31.
- [7] Schwannoma. From Wikipedia, the free encyclopedia. Available at url. <http://en.wikipedia.org/wiki/Schwannoma> (Accessed on 21st August, 2012).
- [8] Julow J. Neurinoma of spinal accessory nerve: Report of two cases. *Acta Neurochir (Wein)* 1983; 69: 219-24.
- [9] Jayaraman M, Smirniotopoulos JG, Davis LM, Patel MR, Krasny RM. Imaging in cranial nerve schwannoma. Available at url. <http://emedicine.medscape.com/article/336141-overview> (Accessed on 21st August, 2012).

### PARTICULARS OF CONTRIBUTORS:

1. Ex-Resident, Department of General Surgery, Government Medical College and Rajindra Hospital, Patiala 147001, India.
2. Professor & Head, Department of General Surgery, Government Medical College and Rajindra Hospital, Patiala 147001, India.
3. Assistant Professor, Department of Pharmacology, Gian Sagar Medical College, Ram Nagar, Rajpura, Patiala 140601, India.
4. Assistant Professor, Department of Pharmacology, Gian Sagar Medical College, Ram Nagar, Rajpura, Patiala 140601, India.

### NAME, ADDRESS, E-MAIL ID OF THE CORRESPONDING AUTHOR:

Dr. Prithpal Singh Matreja,  
Assistant Professor, Department of Pharmacology, Gian Sagar Medical College and Hospital, Ramnagar, Patiala, India.  
Phone: + 91-9855001847, +91-1762-507118  
Fax: +91-1762-520024, Email: drpsmatreja@yahoo.co.in

Date of Submission: **Sep 22, 2012**  
Date of Peer Review: **Jan 28, 2013**  
Date of Acceptance: **Apr 25, 2013**  
Date of Publishing: **Aug 01, 2013**

**FINANCIAL OR OTHER COMPETING INTERESTS:** None.